

## Measurement of forces generated during distraction of growing-rods in early onset scoliosis

Marco Teli, Giuseppe Grava, Victor Solomon, Giuseppe Andreoletti, Emanuele Grismondi, Jay Meswania

Marco Teli, Consultant Orthopaedic Surgeon, Orthopaedic Spine Unit, Policlinico San Marco, Corso Europa 7, 24040 Osio Sotto, Bergamo, Italy

Giuseppe Grava, Victor Solomon, Giuseppe Andreoletti, Consultant Orthopaedic Surgeon, Orthopaedic Department, Policlinico San Marco, Corso Europa 7, 24040 Osio Sotto, Bergamo, Italy

Emanuele Grismondi, Staff Grade Surgeon, Orthopaedic Department, Policlinico San Marco, Corso Europa 7, 24040 Osio Sotto, Bergamo, Italy

Jay Meswania, Biomedical Engineer, Royal National Orthopaedic Hospital, Stanmore, United Kingdom

Author contributions: Teli M and Meswania J designed and obtained the experimental data; Meswania J put the data into charts and did the analysis; Teli M, Grava G, Solomon V, Andreoletti G and Grismondi E revised the data and wrote the text. Correspondence to: Dr. Marco Teli, Consultant Orthopaedic Surgeon, Orthopaedic Spine Unit, Policlinico San Marco, Residence Grancia, Via Tevere 7, 20020 Lainate, Milano, Italy. [marcoteli@hotmail.com](mailto:marcoteli@hotmail.com)

Telephone: +39-02-93559100 Fax: +39-0331-449459

Received: August 19, 2011 Revised: December 28, 2011

Accepted: February 16, 2012

Published online: February 18, 2012

**RESULTS:** Twenty measurements were obtained showing a linear increase of the load with increasing distraction, with a mean peak force of 485 N at 12 mm distraction and a single reading over 500 N. We did not observe bone fractures or ligament disruptions during or after rod elongations. There was one case of superficial wound infection in the cohort.

**CONCLUSION:** The safe peak force carrying capacity of a motorized device for distraction of growing-rods is 500N.

© 2012 Baishideng. All rights reserved.

**Key words:** Early onset scoliosis; Spinal deformity; Growing-rods; Spinal elongation; Force measurement

**Peer reviewer:** Yong Hu, PhD, Assistant Professor, Department of Orthopaedics and Traumatology, The University of Hong Kong 12 Sandy Bay Road, Hong Kong, China

Teli M, Grava G, Solomon V, Andreoletti G, Grismondi E, Meswania J. Measurement of forces generated during distraction of growing-rods in early onset scoliosis. *World J Orthop* 2012; 3(2): 15-19 Available from: URL: <http://www.wjgnet.com/2218-5836/full/v3/i2/15.htm> DOI: <http://dx.doi.org/10.5312/wjo.v3.i2.15>

### Abstract

**AIM:** To measure the forces applied during distraction of growing-rods in early onset scoliosis (EOS), aimed at developing a motorized elongation device.

**METHODS:** A consecutive series of measurements were carried out to analyze the forces applied by the surgeon during distraction of single growing-rods in 10 patients affected by EOS (mean age 8.3 years; range 6 to 10 years) undergoing the first distraction 6 months following implantation of the rods. For each measurement, output from the transducer of a dedicated pair of distraction calipers was recorded at zero load status and at every 1 mm of distraction, up to a maximum of 12 mm for each of the two connected rods.

### INTRODUCTION

Early onset scoliosis (EOS) is a deformity of the growing spine, affecting children before the age of complete lung maturation, i.e., 8 years to 10 years. Growing children with progressive spinal deformity resistant to casting and/or bracing have been treated for four decades with “spinal instrumentation without fusion” or growing-rods. The term encompasses a range of posterior spinal instrumentation techniques – namely single or dual growing rods and expandable ribs, pursuing the

common goal of progressive deformity correction without halting the growth of the spine and lungs<sup>[1]</sup>.

Paul Harrington<sup>[2]</sup> in 1962 described the use of a single, threaded growing-rod on the concave side of the deformity, reporting poor results due to spontaneous fusion and a 11% incidence of rod failure. Marchetti *et al*<sup>[3]</sup> later added end vertebrae fusion to limit rod displacement without reporting definitive results. Luque described the use of two rods with segmental wiring without the necessity for any external support<sup>[4]</sup>. For this technique, which is still in use with modifications<sup>[5]</sup>, variable percentages of success and implant failure are reported. Moe *et al*<sup>[6]</sup> developed the use of a sub-cutaneous growing-rod in an attempt to limit the incidence of implant failure and infection. They achieved good mean curvature control and a 3.8 cm mean spinal growth (SG) at follow-up, at the expense of a 50% rod failure and 15% infection rate. Klemme *et al*<sup>[7]</sup> reported on the use of a sub-fascial rod and achieved 3.1 cm mean SG, with an 8% rod failure and a 15% infection rate. Mineiro *et al*<sup>[8]</sup> reported on the results of sub-cutaneous growing rods (with or without anterior apical fusion) and achieved 2.0 cm mean SG, with 42% rod failure and 9% infection rates. Finally, Akbarnia *et al*<sup>[9]</sup> reported on the use of two parallel growing-rods implanted sub-fascially with a connector for periodic lengthening, achieving 4.6 cm mean SG, with a 22% rate of implant failure and a 9% rate of deep infection. With all growing-rods techniques, the child needs to undergo repeated surgeries, at intervals of 6 mo to 9 mo<sup>[1]</sup>, and once maximum spinal growth has been reached, definitive spinal fusion is performed. It is arguable, from the review of the literature and our own experience with the technique, that limiting the number of open surgeries would decrease the incidence of infection and limit the risks correlated with repeated general anesthesia. To this end, Takaso *et al*<sup>[10]</sup> tested a motorized device for closed growing-rod distraction on a canine model of induced scoliosis. Near-complete correction was obtained in awake animals by remote-controlled rod distraction at 3 wk intervals, with a pre-tested distraction peak force of the device of 194 N. If similar devices are to be designed and applied in clinical use, it is necessary to measure the force pattern generated during surgical distraction of growing-rods. The aim of this study was therefore to measure and analyze the pattern of such forces in children affected by EOS.

## MATERIALS AND METHODS

Ten children affected by EOS resistant to conservative treatment underwent scheduled surgical distractions of single growing-rods, 6 mo after first implantation and distraction. The sample group consisted of 4 males and 6 females aged on average 8.3 years (range 6 years to 10 years) at the time of surgery. Etiologies of deformities included idiopathic scoliosis in 4 cases, syndromic scoliosis in 3 cases, post-surgical scoliosis in 2 cases and arthrogyposis multiplex congenital (AMC) in 1 case. Sur-

geries were consecutively performed at a single center for spinal diseases by a team of spinal deformity surgeons. All patients' were skeletally immature at the time of surgery, as demonstrated by spinal posteroanterior X-rays (absence of ossification of both the iliac apophyses and the triradiate cartilages). Prior to the present surgery, growing rods had been implanted in sub-fascial position on the concavity of the coronal curvature<sup>[1,2,6-8]</sup>. Stainless steel 4.5 mm diameter pediatric Cotrel-Dobousset rods (Medtronic Sofamor Danek, Inc., Memphis TN, United States) had been used in all patients. Laminar hooks and/or pedicle screws had been used at the bottom end vertebrae and laminar plus pedicle hooks at the top ones, in a claw-like configuration (Figure 1). End vertebrae had been decorticated and no bone graft was added locally to enhance fusion. Following the first implantation, patients had been kept on molded plastic braces until the scheduled distraction. Local fusion performed at the end vertebrae was assessed by postero-anterior and lateral full spine radiographs prior to the scheduled distraction. No patient had had an anterior growth-arrest procedure.

A special pair of distraction calipers similar to those commercially available was manufactured, incorporating a load transducer to allow the measurement of force applied at the tip of the calipers. Included in the design was a millimeter scaled ruler (Figure 2). The calipers were load tested and calibrated to demonstrate repeatability, with accuracy of less than 1% of the full scale deflection. The accuracy of the displacement measurement using a ruler in a surgical environment was considered to be  $\pm 0.25$  mm. Output from the transducer was recorded by dedicated software and represented as a load-displacement (distraction) plot (Figure 3).

For the distraction of growing-rods, patients were positioned prone under general anesthesia and monitoring of somatosensory spinal evoked potentials. The rod connector and 50 mm of each rod were exposed through a centered skin incision and opening of the fascia. This was followed by serial loosening of the connector locking nuts and placement of the distraction calipers against a firm rod-holder. As the first rod started to be distracted, output from the transducer was recorded at zero load and at every 1mm increment up to the greatest distraction achievable until the limit of 12 mm<sup>[9-11]</sup>. A 10 s sample interval was observed in order to allow for the visco-elastic properties of the spinal soft tissues to act<sup>[9-11]</sup>. This process was repeated for the second rod, measuring the output from the transducer. After the elongation was completed, new nuts were tightened to the rod connector and wound closure was performed in layers. Patients were mobilized in their braces as soon as tolerated and discharged without exception on the day following surgery.

## RESULTS

A total of 20 force measurements were performed during rod distraction on the ten patients. Table 1 displays

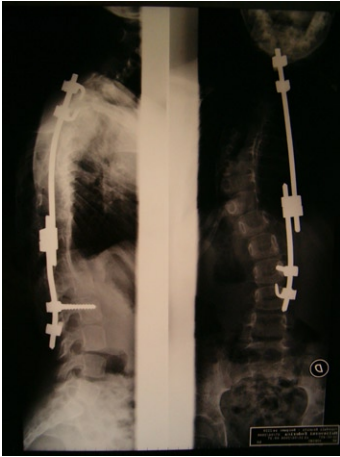

Figure 1 Lateral and postero-anterior spinal films after implantation of growing-rods.




Figure 2 Distraction calipers.

features of pre and post-distraction spinal deformities as mean  $\pm$  SD values. The mean 19.2 mm total distraction was the result of the elongation of both rods until a maximum of 12 mm per rod. The elongation of each rod stopped when the surgeon reached 12 mm and/or maximum effort had been transferred to the elongation. Minimal corrections were obtained in Cobb angles, indicating that first distractions mainly re-tension implants on a growing spine<sup>[1-3,6-8]</sup>. Table 2 displays the minimum, mean and maximum forces per millimeter of rod distraction. Tension forces ranged from a mean of 133 N at 1 mm distraction to a mean of 485 N at 12 mm distraction. The tension force reached a maximum of 552 N at 6mm distraction of one of the two rods in the patient affected by AMC.

Figure 3 shows how the minimum, mean and maximum forces steadily increased with distraction of the rods up to the above reported peak. The graph also indicates that there was a pre-load on the rod that needed to be overcome before any elongation could be achieved. Once the pre-load was overcome, there appeared to be a linear relationship between the load and elongation. Notably, the surgeon needed to apply mean forces of similar magnitude to achieve 10 mm and 12 mm of distraction. In 7 out of 10 measurements, the upper limit

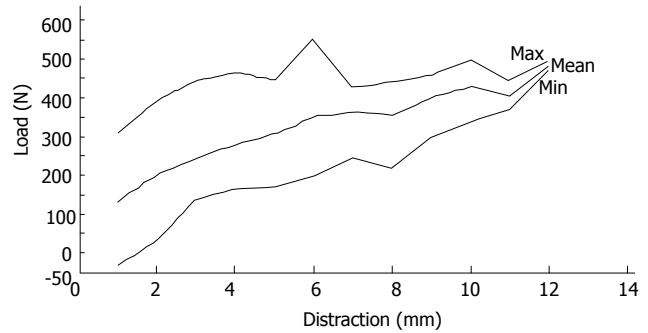


Figure 3 Force/distraction plot: maximum (top curve), mean (middle curve) and minimum (bottom curve) values.

of distraction for a single rod was 10 mm.

These experimental data corresponded clinically to a small improvement in both the coronal and sagittal mean spinal deformity angles ( $3.6^\circ$  and  $4.4^\circ$  respectively,  $P < 0.05$ , Student's paired  $t$  test), and to a satisfactory 19.2 mm mean lengthening of the implants obtained with surgery (Table 1).

There were no instances of fracture of the posterior vertebral elements or implant failure during or after distraction. One out of the 10 cases had delayed wound healing that required one week of oral antibiotic treatment after S. Epidermidis was grown from the wound culture. There were no instances of neurological deficits or medical complications after surgery in the cohort.

## DISCUSSION

Infection and implant failure are the two main limitations of the current growing-rod techniques<sup>[1-9]</sup>. It is easy to understand how the first issue might greatly benefit from limiting the number of open surgeries that patients need to undergo in order to achieve progressive correction and spinal growth. Implant failure, seemingly a function of the length of treatment with growing rods, may be due to rod loosening or indirectly to fracture of the posterior elements, mainly the laminae<sup>[8,9]</sup>. Possibly, this problem could be also addressed by distracting the growing-rod system non-surgically at closer intervals than the 6 mo to 9 mo routine<sup>[1,10]</sup>. Developing a closed distraction mechanism ready for clinical use, as it was the case with extendible endoprostheses in limb tumor surgery<sup>[11]</sup>, could be one of the steps towards better results of spinal instrumentation without fusion in the treatment of early onset scoliosis. To do so, it was necessary to measure the magnitude of the forces generated *in vivo* by a surgeon distracting a growing-rod system.

No data have been reported prior to this study on the magnitude of the forces generated during distraction of growing-rods in children. It is known however that the load to failure of a thoracic lamina instrumented with a hook is around 670 N in the adolescent<sup>[12]</sup> and that recommended values of distraction force with Harrington instrumentation did not exceed 400 N<sup>[13]</sup>. In our patients, growing-rods were positioned on the concavity of the

**Table 1 Spinal deformity angles**

	Mean	SD	P value (t - test)
Pre-distraction PA cobb	53.8	19.9	
Post-distraction PA cobb	50.2	20	0.003
Pre-distraction Lat cobb	46.2	13.7	
Post-distraction Lat cobb	41.8	13.5	0.006
Rods distraction (mm)	19.2	4.4	

**Table 2 Force/distraction values**

Distraction (mm)	Min. load (N)	Mean load (N)	Max. load (N)
1 (min)	-32 (min)	133 (min)	311 (min)
2	30	203	394
3	141	247	447
4	167	282	465
5	172	308	447
6	201	354	552 (max)
7	246	364	428
8	222	354	440
9	303	402	461
10	342	430	497
11	370	404	445
12 (max)	472 (max)	485 (max)	498

scoliotic curve like Harrington rods, and the attachment to bone was *via* pedicle screws or laminar hooks at the bottom levels, lower thoracic or lumbar, and *via* laminar and pedicle hooks at the upper thoracic levels. Therefore, it is possible to compare our mean peak distraction force of 485 N with that of the above studies. As described above, the recorded peak force exceeded the 500 N threshold in a single patient with the likely reason that soft tissues in patients affected by AMC have peculiar mechanical properties<sup>[14]</sup>. Also, a negative force of -32 N was recorded at minimum distraction in a single case. This could be due to the fact that very little load is normally applied in a confined space like that occupied by the distraction tool. These factors might limit the significance of the results of the study.

Despite applying forces of this magnitude, in our series there was no failure of the bone-implant interface and good maintenance of deformity with satisfactory spinal elongation. Not surprisingly, small improvements in deformity angles have been observed with distractions in this study, because the main correction normally takes place at the time of the first implantation<sup>[1-9]</sup>.

Transferring the experimental data described in the study to the development of a motorized device for closed distraction would take into account several factors: firstly, the position of the rods with respect to the concavity of the curve; and secondly, the load transfers from the rods to the vertebral bone and the presence of friction within the device itself. The device would be made of two rods connected via a central gear housing an electrical motor to replicate the force vector obtained with positioning of the single growing-rods. The bone-implant interface will replicate the pedicle screws and claw-like hooks design described above (Figure 1). Fi-

nally, we estimate that the magnitude of the forces measured during growing-rods distraction certainly includes any frictional losses in the locking mechanisms that will be taken up by the motorized system. Therefore, we would recommend the peak force carrying capacity of a motorized device for growing-rod extension not to exceed the mean level of 485 N measured in this study.

## COMMENTS

### Background

The treatment of early onset scoliosis is surgical when resistant to casts and braces and progressive. Growing-rods are often used but need repeated open surgeries to achieve their effect.

### Research frontiers

Growing-rods are normally elongated every 6-8 mo according to spinal growth. Closed elongation procedures are not applied today because (1) no data existed on the forces involved *in vivo* before the present study was undertaken; and (2) technology of closed elongation had only been applied to mammals in the laboratory.

### Innovations and breakthroughs

It is now known that the forces applied in elongation of growing rods in children affected by early onset scoliosis reach a maximum level of 500 N, with a pattern that reproduces the visco-elastic features of the human spine.

### Applications

Data retrieved by this study can be applied to the development of a closed, motorized elongation growing-rod system to save children affected by early onset scoliosis from repeated surgeries.

### Terminology

Early onset scoliosis is a spinal deformity that develops before the age of lung maturation (8 years to 10 years) and that can impair lung development for the rest of life. Growing-rods are a particular form of spinal instrumentation that allows correction of spinal deformity while allowing lung and spinal growth.

### Peer review

This is a valuable article with good performances.

## REFERENCES

- 1 **Thompson GH**, Akbarnia BA, Campbell RM. Growing rod techniques in early-onset scoliosis. *J Pediatr Orthop* 2007; **27**: 354-361
- 2 **HARRINGTON PR**. Treatment of scoliosis. Correction and internal fixation by spine instrumentation. *J Bone Joint Surg Am* 1962; **44-A**: 591-610
- 3 **Marchetti PG**, Faldini A. End fusion in the treatment of some progressing or severe scoliosis in childhood or early adolescence. *Orthop Trans* 1978; **2**: 271
- 4 **Luque ER**. Paralytic scoliosis in growing children. *Clin Orthop Relat Res* 1982; **163**: 202-209
- 5 **Pratt RK**, Webb JK, Burwell RG, Cummings SL. Luque trolley and convex epiphysiodesis in the management of infantile and juvenile idiopathic scoliosis. *Spine (Phila Pa 1976)* 1999; **24**: 1538-1547
- 6 **Moe JH**, Kharrat K, Winter RB, Cummine JL. Harrington instrumentation without fusion plus external orthotic support for the treatment of difficult curvature problems in young children. *Clin Orthop Relat Res* 1984; **185**: 35-45
- 7 **Klemme WR**, Denis F, Winter RB, Lonstein JW, Koop SE. Spinal instrumentation without fusion for progressive scoliosis in young children. *J Pediatr Orthop* 1997; **17**: 734-742
- 8 **Mineiro J**, Weinstein SL. Subcutaneous rodding for progressive spinal curvatures: early results. *J Pediatr Orthop* 2002; **22**: 290-295
- 9 **Akbarnia BA**, Marks DS, Boachie-Adjei O, Thompson AG, Asher MA. Dual growing rod technique for the treatment of

- progressive early-onset scoliosis: a multicenter study. *Spine (Phila Pa 1976)* 2005; **30**: S46-S57
- 10 **Takaso M**, Moriya H, Kitahara H, Minami S, Takahashi K, Isobe K, Yamagata M, Otsuka Y, Nakata Y, Inoue M. New remote-controlled growing-rod spinal instrumentation possibly applicable for scoliosis in young children. *J Orthop Sci* 1998; **3**: 336-340
  - 11 **Schindler OS**, Cannon SR, Briggs TW, Blunn GW. Stanmore custom-made extendible distal femoral replacements. Clinical experience in children with primary malignant bone tumours. *J Bone Joint Surg Br* 1997; **79**: 927-937
  - 12 **Waugh TR**. Intraoperative measurements during instrumental correction of idiopathic scoliosis. *Acta Orthop Scand* 1966; **93S**: Suppl 93: 1-9387
  - 13 **Dunn HK**, Daniels AU, McBride GG. Intraoperative force measurements during correction of scoliosis. *Spine (Phila Pa 1976)* 1982; **7**: 448-455
  - 14 **Yingsakmongkol W**, Kumar SJ. Scoliosis in arthrogryposis multiplex congenita: results after nonsurgical and surgical treatment. *J Pediatr Orthop* 2000; **20**: 656-661

**S- Editor** Yang XC **L- Editor** Roemmele A **E- Editor** Yang XC